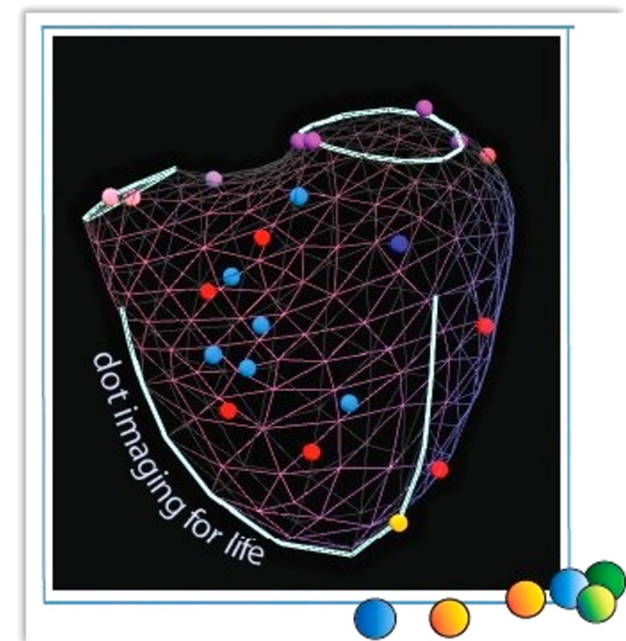

VMS+ Quick Reference Guide



Copyright © 2018 Ventripoint Diagnostics Ltd.

Copyright © 2018 VMS™, VMS-PLUS™, VMS+™ are brands of Ventripoint Diagnostics Ltd.
All rights reserved.

Quick Reference Guide

- Place ECG Electrodes on patient using Lead II configuration.
- Place Transmitter over the patient taking care to center directly over the Parasternal acoustic window. Ensure that the transmitter is no Closer than 22cm to the Ultrasound transducer during parasternal imaging.
- Ensure proper Transmitter location by placing Ultrasound transducer at Apical acoustic window and ensure the distance is not “OUT OF RANGE”.
- Discuss breathing technique with patient: All images are to be acquired at end-expiration.
- Since the patient cannot move after acquiring the first image confirm the optimal position & depth for all windows.
- Each section of this guide represents a chamber of the heart (RV, LV, RA & LA).

Point Placement on Recommended Views

View	Right Atrium Points	Left Atrium Points
True Apical 4-Ch	Tricuspid Annulus x 2 RA Endocardium x 4	Mitral Annulus x 2 LA Endocardium x 4
Apical 2-Ch (VLA view)		Mitral Annulus x 2 LA Endocardium x 4
PLAX LVOT		Mitral Annulus x 2 LA Endocardium x 3
Apical LAX 3-Ch view		Mitral Annulus x 2 LA Endocardium x 3
PLAX RVIT	Tricuspid Annulus x 2 RA Endocardium x 2	
PSAX at Aortic Valve	Tricuspid Annulus x 1 RA Endocardium x 3	
Subcostal IVC	RA Endocardium x 3	



CAUTION: Once first image is acquired, any movement of the Transmitter Arm will cause poor results. DO NOT allow the Transmitter Arm to move after the study is started.



No part of this document may be reproduced, transmitted in any form or by any means, electronic, mechanical, or otherwise, including photocopying, recording or information storage and retrieval systems, or translated into any language for any purpose without the prior written permission of Ventripoint Diagnostics Ltd.

Point Placement on Recommended Views

View	Right Ventricle Points	Left Ventricle Points
True Apical 4-Ch	Tricuspid Annulus x 2 RV Septum x 2 RV Endocardium x 2 Basal Bulge x 1 Apex x 1	Mitral Annulus x 2 LV Endocardium x 4 Apex x 1
Apical 2-Ch (VLA view)		Mitral Annulus x 2 LV Endocardium x 4
PLAX LVOT	RV Septum x 2 RV Endocardium x 3	Aortic Annulus x 2 Mitral Annulus x 2 LV Endocardium x 4
PLAX RVIT	Tricuspid Annulus x 2 RV Endocardium x 3	
PLAX RVOT	Pulmonic Annulus x 1 RV Endocardium x 1 RV Septum x 1	
PSAX at Aortic Valve	RV Endocardium x 2 Pulmonic Annulus x 1 Conal Septum x 1	
PSAX at Papillary	RV Endocardium x 2 RV Septal Edge x 2 RV Septum x 1	LV Endocardium x 4
PSAX at Apex	RV Septal Edge x 2	

- For each chamber use the recommended views, *True Apical 4-Ch*, *RVOT*, *LVOT* and etc.
- Please ensure for each view the minimum required points are placed in both the **ED** and **ES** frames.
- Identify each Echo View using the **Annotate** button on the right.
- See the table at the top of each image in this guide that specifies the number of points to place.

Show	Structures	Count
<input checked="" type="checkbox"/>	RV Endocardium	3
<input checked="" type="checkbox"/>	RV Septum	2
<input checked="" type="checkbox"/>	Pulmonic Annulus	3
<input checked="" type="checkbox"/>	Conal Septum	1
<input checked="" type="checkbox"/>	Tricuspid Annulus	3
<input checked="" type="checkbox"/>	Basal Bulge	0
<input checked="" type="checkbox"/>	Apex	1
<input checked="" type="checkbox"/>	RV Septal Edge	0

- On the PC, the *Count* column beside the *Structures* column in the table on top right of the screen will turn green once you reach the required number of points for that structure
- Once the required number of points have been placed, the **Run** button will become active.

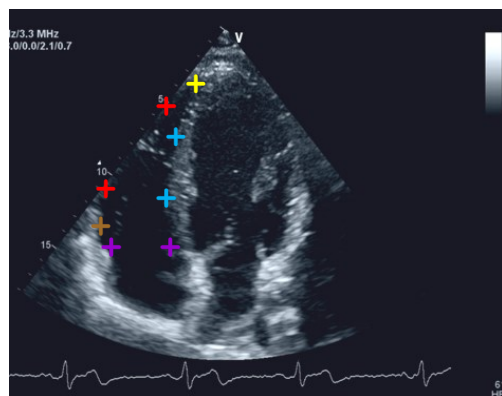
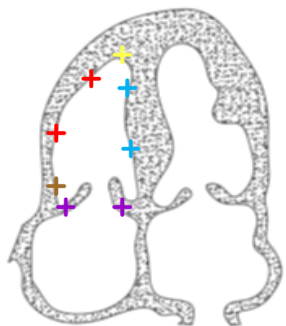


NOTE: For best results, place points in the order shown in table above the image in this guide

Right Ventricle

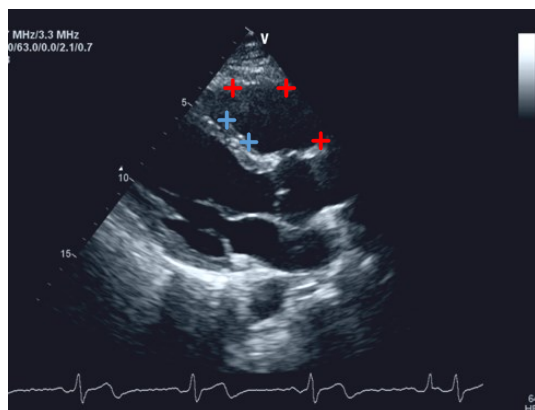
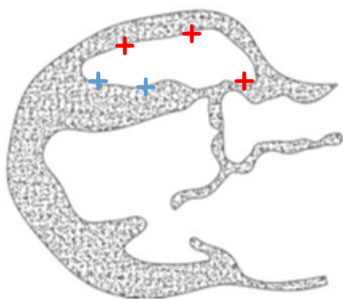True Apical 4-Ch	Tricuspid Annulus x 2	+
	RV Septum x 2	+
	RV Endocardium x 2	+
	Basal Bulge x 1	+
	Apex x 1	+

Apical 4CH



PLAX LVOT	RV Septum x 2	+
	RV Endocardium x 3	+

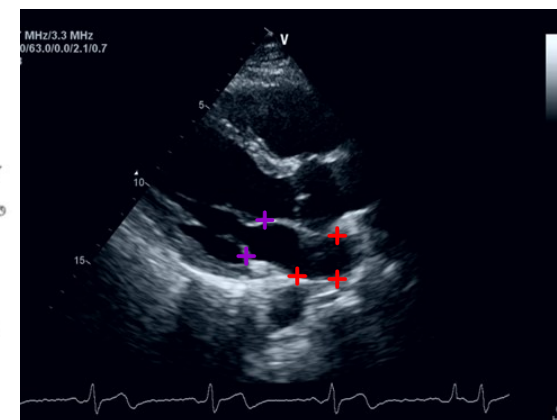
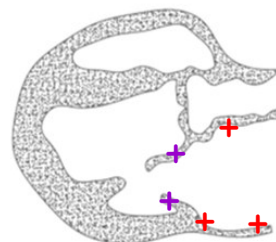
PLAX



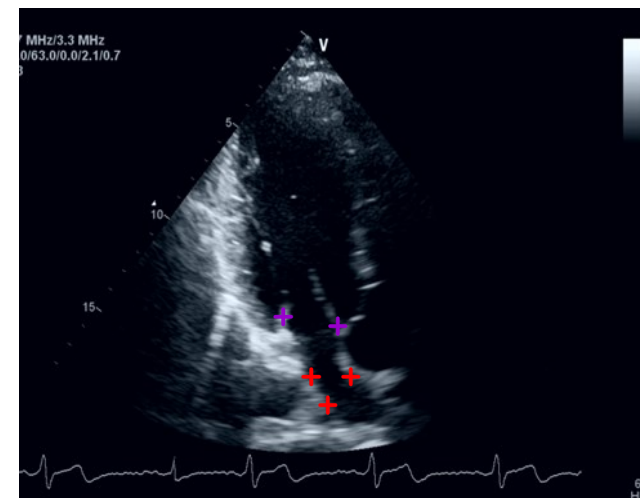
Left Atrium

PLAX LVOT	Mitral Annulus x 2	+
	LA Endocardium x 3	+

PLAX

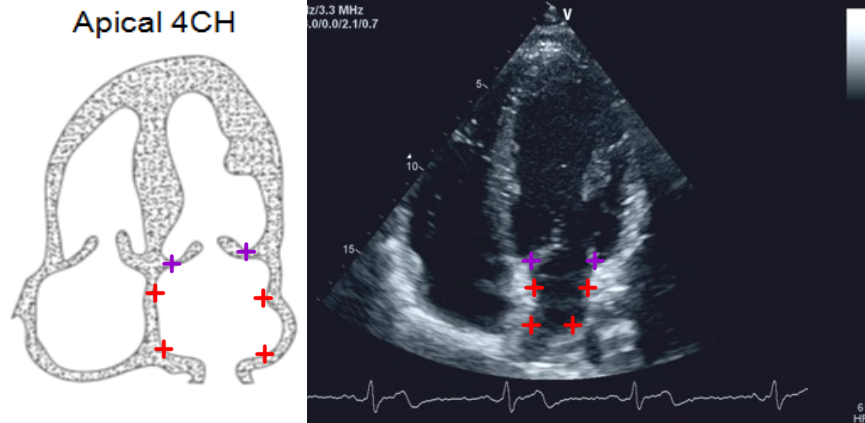


Apical LAX 3-Ch view	Mitral Annulus x 2	+
	LA Endocardium x 3	+

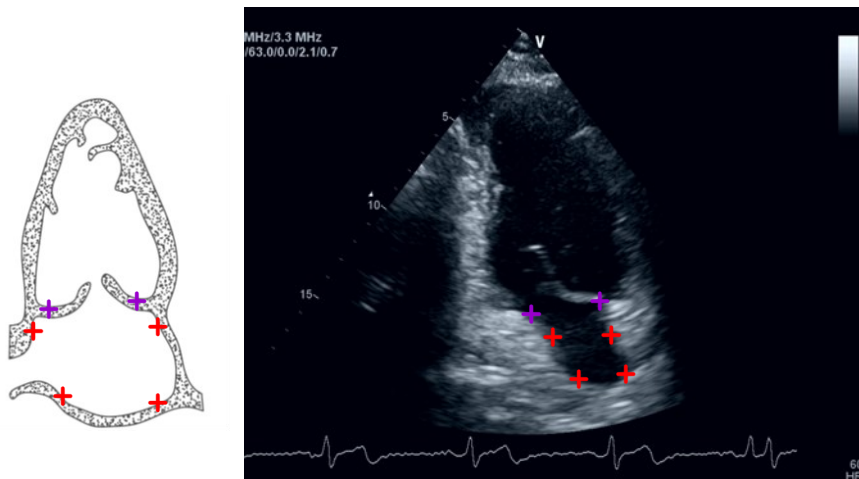


Left Atrium

True Apical 4-Ch	Mitral Annulus x 2	+
	LA Endocardium x 4	+

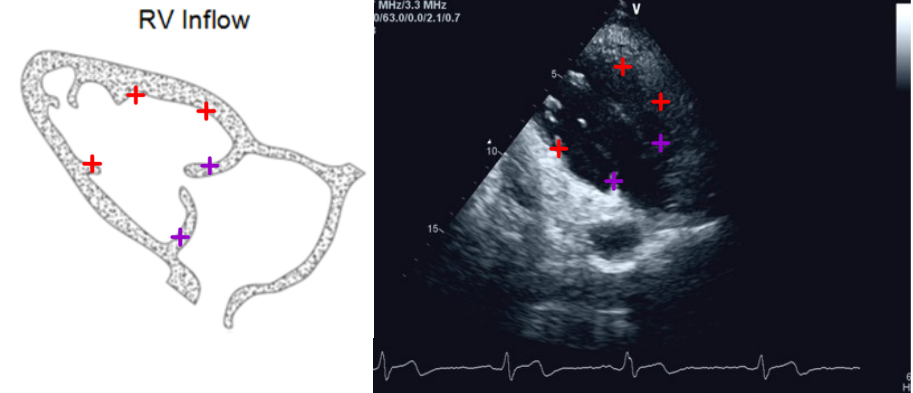


Apical 2-Ch (VLA)	Mitral Annulus x 2	+
	LA Endocardium x 4	+

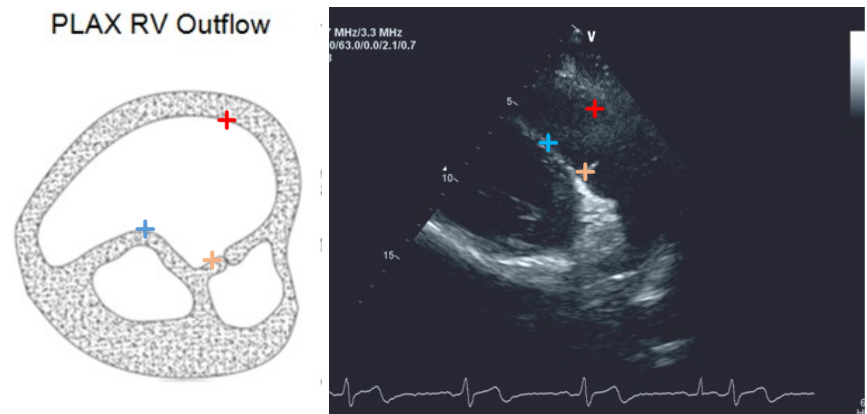


Right Ventricle

PLAX RVIT	Tricuspid Annulus x 2	+
	RV Endocardium x 3	+



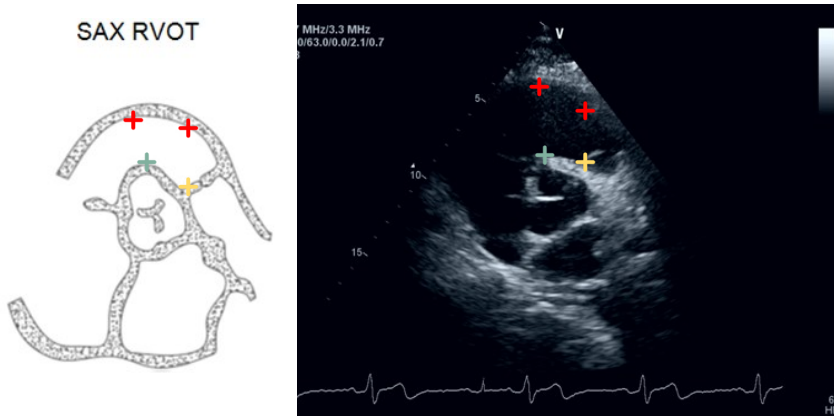
PLAX RVOT	Pulmonic Annulus x 1	+
	RV Endocardium x 1	+
	RV Septum x 1	+



Right Ventricle

PSAX at Aortic Valve	RV Endocardium x 2	+
	Pulmonic Annulus x 1	+
	Conal Septum x 1	+

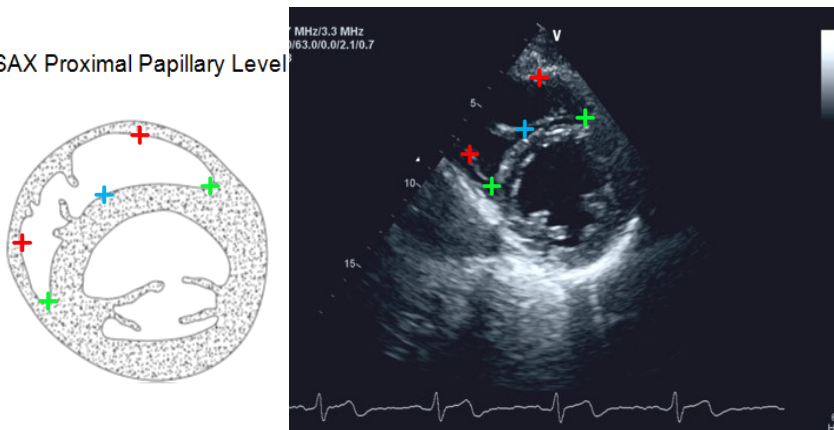
SAX RVOT



PSAX at Papillary

PSAX at Papillary	RV Endocardium x 2	+
	Septal Edge x 2	+
	RV Septum x 1	+

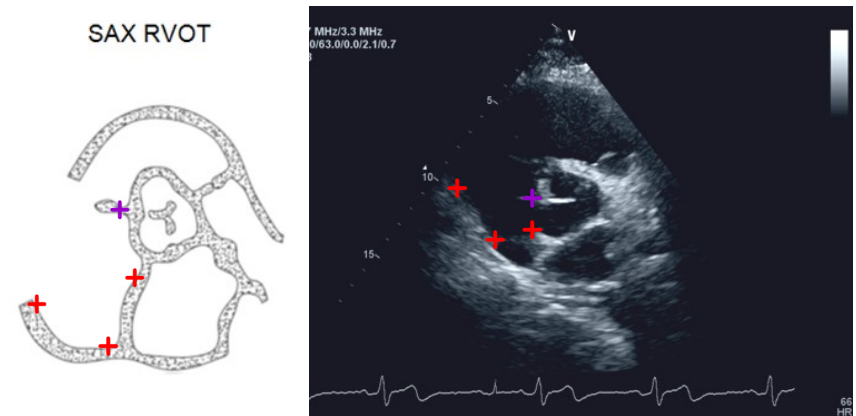
SAX Proximal Papillary Level



Right Atrium

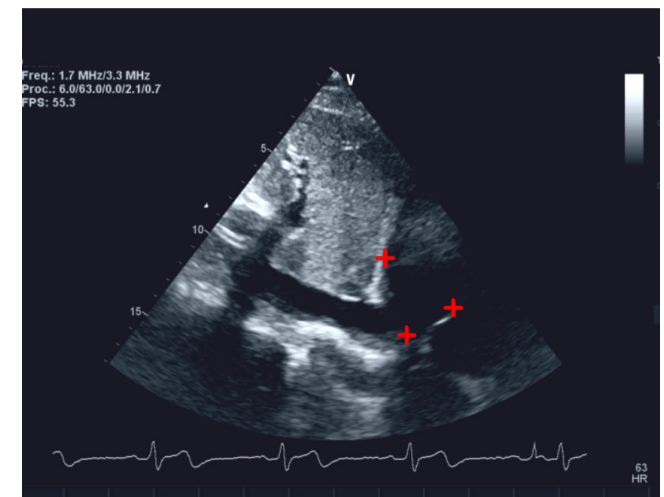
PSAX at Aortic Valve	Tricuspid Annulus x 1	+
	RV Endocardium x 3	+

SAX RVOT



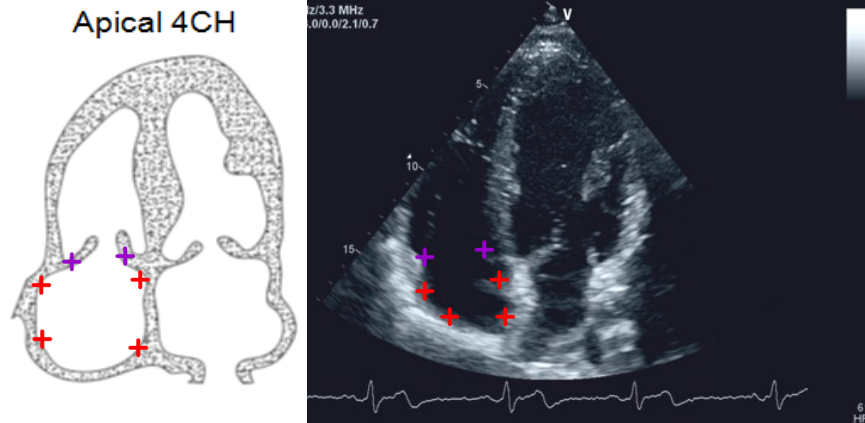
Subcostal IVC

Subcostal IVC	RA Endocardium x 3	+
----------------------	--------------------	---

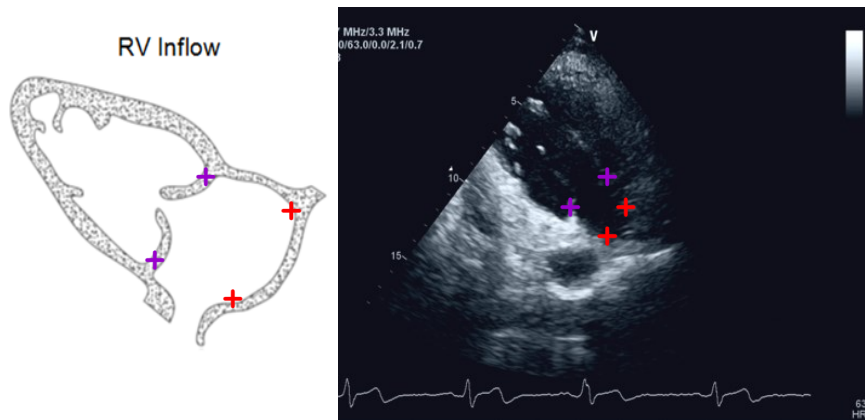


Right Atrium

True Apical 4-Ch	Tricuspid Annulus x 2	+
	RA Endocardium x 4	+

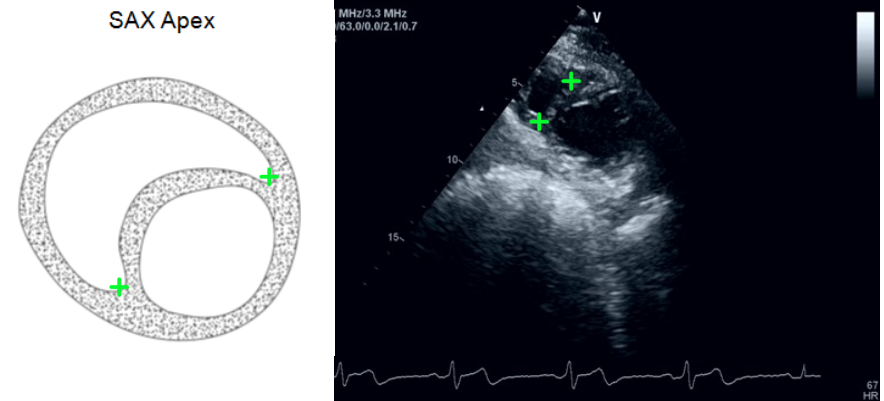


PLAX RVIT	Tricuspid Annulus x 2	+
	RA Endocardium x 2	+



Right Ventricle

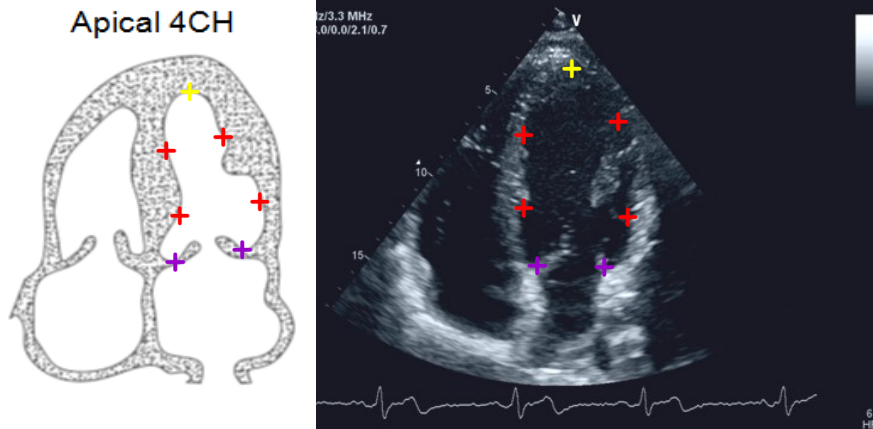
PSAX at Apex	RV Septal Edge x 2	+
---------------------	--------------------	---



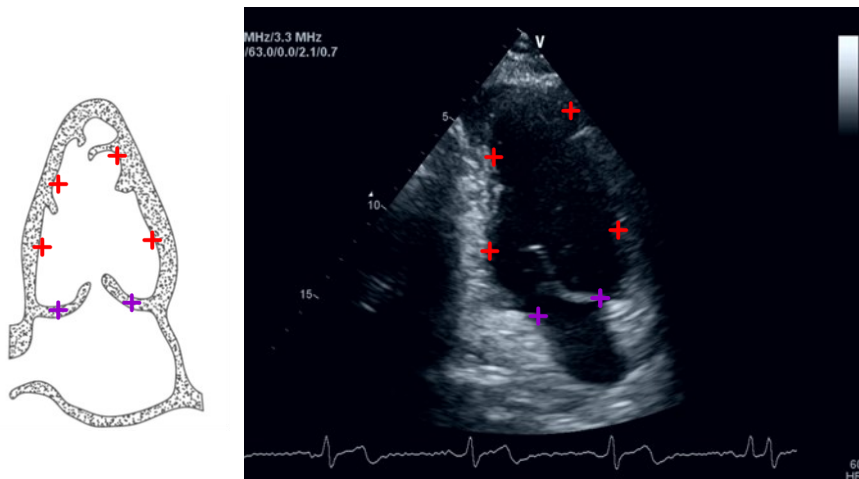
CAUTION: Be careful when selecting **ED** and **ES**. If your selections need to be corrected at a later date, any existing work will be lost.

Left Ventricle

True Apical 4-Ch	Mitral Annulus x 2	+
	LV Endocardium x 4	+
	Apex x 1	+

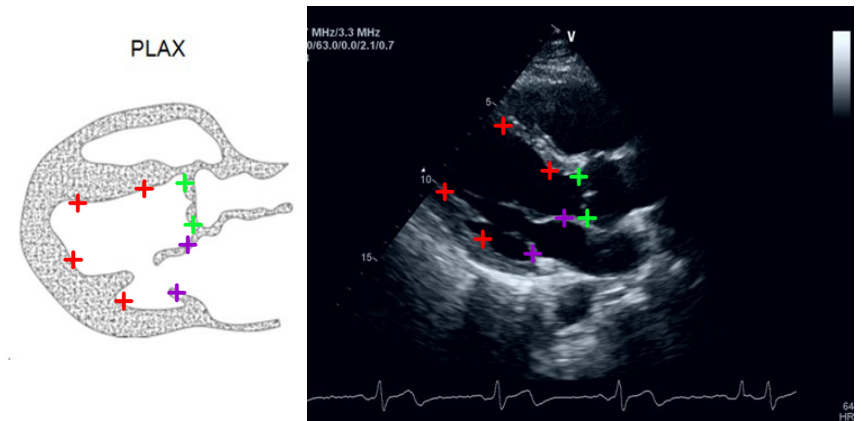


Apical 2-Ch (VLA)	Mitral Annulus x 2	+
	LV Endocardium x 4	+



Left Ventricle

PLAX LVOT	Aortic Annulus x 2	+
	Mitral Annulus x 2	+
	LV Endocardium x 4	+



PSAX at Papillary	LV Endocardium x 4	+
----------------------	--------------------	---

